

DOI:

Sharp needle recanalization for salvaging hemodialysis accesses with chronically occluded peripheral outflow

Gregg A. Miller¹, Elsie Koh^{1,2}, Aleksandr Khariton¹, Dean C. Preddie^{1,3}, Wayne W. Hwang¹, Yevgeny Savransky⁴, Israel Schur⁵

¹American Access Care of Brooklyn, Brooklyn, NY - USA

²Access Care Physicians, Verona, NJ - USA

³Columbia University College of Physicians and Surgeons, New York, NY - USA

⁴American Access Care of Bellmore, Bellmore, NY - USA

⁵American Access Care of New York, New York, NY - USA

ABSTRACT

Purpose: To assess the effectiveness of sharp needle recanalization (SNR) for treatment of chronically occluded venous outflow in hemodialysis access.

Methods: A retrospective analysis of patient records from January 2006 to March 2010 was conducted. Forty-four hemodialysis patients (31 fistulas, 13 grafts) were referred for arm swelling (18%), excessive bleeding after dialysis (29%), and thrombosis (53%). All patients had chronic occlusion of the outflow vein which failed conventional recanalization techniques. A new outflow pathway was established by advancing a 21g needle and dilating the subcutaneous tract to bridge the fistula body to a juxtaposed patent vein. If necessary, uncovered or covered stents were utilized to maintain patency of the newly formed subcutaneous tract.

Results: Forty-four patients underwent 45 SNR procedures, with restoration of normal function and complete relief of symptoms in 40 (91%) patients. The average tract length was 15 mm (range, 1 to 32) and the average dilatation diameter was 8 mm. During the initial SNR procedure, bare metal (n=21) or covered (n=5) stents were inserted in 26 patients. The average follow-up was 18.4 months (range, 0.2 to 48 months). No major complications were observed with the procedure. At 12 months, the primary access, primary tract, and secondary access patencies were 10%, 51%, and 92%, respectively. Percutaneous thrombectomy procedures were performed at a rate of 1.16 per access-year and the number of interventions within the tract was 0.94 per access-year.

Conclusions: Sharp needle recanalization is an effective percutaneous treatment for restoring function to hemodialysis accesses with chronically occluded venous outflow pathways.

Key words: Arteriovenous fistula, Flow re-routing, Surgical revision

Accepted: March 18, 2011

INTRODUCTION

Stenosis of the venous outflow tract has been implicated in 30% to 93% of vascular access failures (1-3). Occlusion of peripheral or central veins with dependent collateral flow is rarer, but generally results in access dysfunction and failure (4).

When venous occlusion results in a failed access, surgical salvage procedures generally consist of synthetic or native vein bypasses. These "jump graft" procedures present numerous technical limitations and are reported to have 12-month secondary access patencies of 24% to 57% (3, 5). The sharp needle recanalization procedure is an image-guided endovascular technique to connect non-contiguous, juxtaposed veins through the subcutaneous space using a 21g micropuncture needle. Sharp needle

recanalization (SNR) is a percutaneous procedure performed in the radiology suite by experienced interventionalists instead of open surgery. This study investigates the use of this technique to treat occluded arteriovenous accesses.

METHODS

Patient population

A retrospective analysis was performed, evaluating outcomes for patients who presented to seven free-standing vascular access outpatient clinics between January 2006 and March 2010. The procedures were performed by eight interventionalists. All patients with an occluded

JVA_11_1018

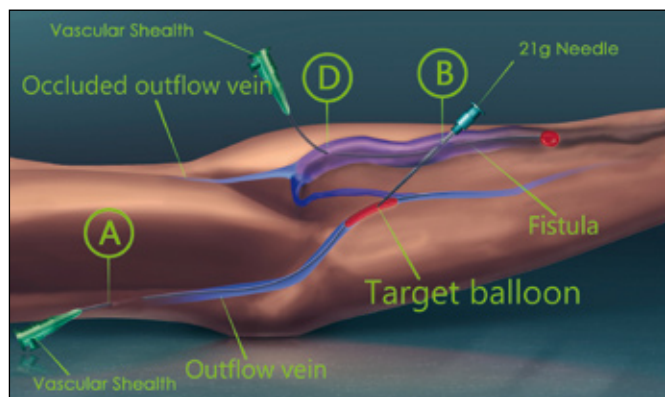


Fig. 1 - An angioplasty balloon is used as a target.

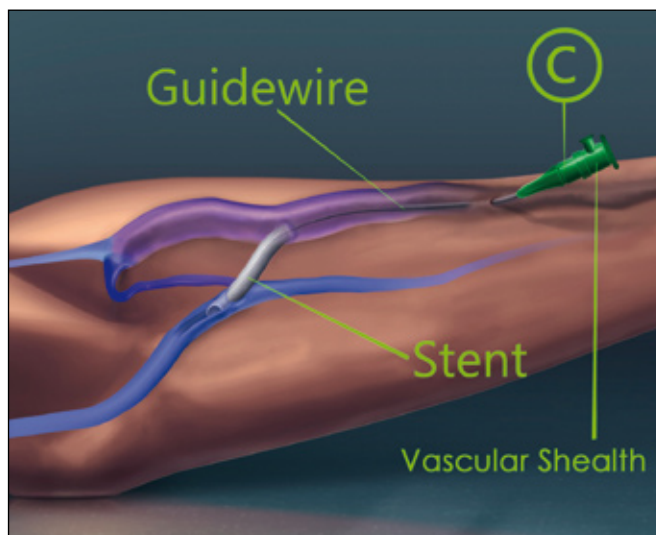


Fig. 2 - A stent is placed to create a bypass channel.

hemodialysis access outflow who underwent an attempt to connect adjacent venous pathways by using a sharp needle were included in the study.

Forty-four patients fulfilled the study criteria, with hemodialysis accesses comprised of 10 upper arm fistulas, 21 radiocephalic fistulas, and 13 forearm grafts (Tab. I). Technical success was achieved in 40/44 (91%) patients and 41/45 (91%) SNR procedures. Co-morbidities included hypertension (80%), diabetes mellitus (39%), acquired immunodeficiency syndrome (7%), congestive heart failure (7%), and arteriosclerosis (2%). The average age of fistulas was 13 months, while the average age of grafts was 4 months.

All patients provided written informed consent for procedures. No institutional review board existed at the authors' institution at the time the study was commenced; therefore, the principles of the Declaration of Helsinki were followed (6).

Procedure

All patients had failed or been deemed ineligible for standard wire-and-catheter recanalization techniques via antegrade or retrograde approaches. Prior to SNR procedures, all patients underwent angiography (GE OEC 9800 plus) and ultrasonography (Terason T3000, 5 MHz probe, Teratech Corp., Burlington, MA; GE LOGIQ Book XP, GE, San Jose, CA, USA) to ascertain the location of an outflow occlusion and a patent vein adjacent to the outflow. The procedure was performed using local anesthesia (1% xylocaine with epinephrine) and intravenous conscious sedation with 50 mg to 200 mg of Fentanyl (fentanyl citrate 50 mcg/mL, from Hospira, Inc., Lake Forest, IL, USA) and 1-4mg Versed (Midazolam HCL 2 mg/2 mL, from Hospira, Inc., Lake Forest, IL, USA). Although all 45 procedures were performed by eight interventionalists, seven interventionalists were mentored by the eighth interventionalist with the procedure described below.

TABLE I - PATIENT DEMOGRAPHICS (N=44)*

Sex	Male = 26 (59)
	Female = 18 (41)
Average Age	59.2 ± 15.5 [SD] years (range, 19–89)
Access	Brachial-Cephalic Fistula = 7 (16)
	Transposed Basilic Vein Fistula = 1 (2)
	Brachial-Basilic Fistula = 1 (2)
	Brachial-Axillary Fistula = 1 (2)
	Radial-Cephalic fistula = 21 (48)
	C-shaped graft = 4 (9)
	Loop graft = 8 (18)
	Straight graft = 1 (2)

*Number (percentage).
SD, standard deviation

Selection of outflow vein. A detailed duplex ultrasound exam was performed to search for an adjacent patent outflow vein. An area was then identified where the main body of the AV access and the selected outflow vein were superficial and sufficiently proximate to each other. The selected outflow vein was accessed in a retrograde manner (access point C, see Fig. 1) under ultrasound guidance, with a micropuncture needle, 4Fr catheter, and placement of a 5Fr vascular sheath. Contrast (Ioxilan 62%, 300 mg/mL, mfg. Guerbet LLC, Bloomington, IN; Visipaque/iodixanol, GE Healthcare, Princeton, NJ, USA) injections were performed and digital images were obtained to confirm patency of the outflow vein.

Preparation. Access was obtained into the main body of the fistula or graft in an antegrade manner (access point A, see Fig. 2) and a 7Fr sheath (Pinnacle R/O II Terumo Medical Corp., Elkto, MD, USA) was inserted. Access was obtained into the access body in a retrograde manner and

a 6Fr vascular sheath was inserted. A compliant balloon catheter was used to ensure inflow could be controlled as required. During dilation of the SNR tract, the inflow was blocked in order to minimize extravasation.

Recanalization. A 21 g needle (Micropuncture Introducer, Cook, Bloomington, IN) was manually bent to a 20-degree curve to enhance control over its directionality. Under ultrasound and fluoroscopic guidance, the needle was advanced into the body of the access (point A), pushed through the outflow occlusion, and then inserted into the adjacent target patent vein at a site central to the occlusion. An inflated angioplasty balloon (6-8mm diameter, Meditech/Boston Scientific, Watertown, MA) was used as a target, improving the accuracy of the distal-to-proximal vein catheterization (Fig. 2). If the target vein had a diameter ≥ 6 mm, no balloon was necessary; if veins were < 6 mm in diameter, an inflated balloon served both to increase the diameter of the target vein and enhance its vascularity.

A 0.018-inch wire was then advanced through the needle and into the target balloon. The balloon was removed, enabling a through-and-through wire to be established. The wire was exchanged for a 4Fr micropuncture dilator catheter (Micro-puncture Introducer; Cook, Bloomington, IN). The inner dilator was removed and a test bolus of contrast was injected to confirm the position in the selected patent outflow vein. The dilator was then exchanged for a 6 or 7Fr sheath, if suitable purchase so allowed. In many instances, the distance from the puncture site (A) to the sharp needle tract was too short to warrant the use of a sheath and the tract was dilated using a sheathless approach. Once the tract was dilated, access point B (Fig. 2) was utilized to pass an angled catheter and hydrophilic wire (Terumo, Tokyo, Japan) through the subcutaneous tract. The newly-created tract and outflow vein underwent sequential balloon dilatation in order to achieve a circumference capable of accommodating the increased blood flowing through this channel. The tract was then further dilated until its diameter was equivalent to that of the connecting vein (a diameter of 6-8mm was generally suitable). After deployment of the stent or stent graft an angioplasty balloon was inserted and used to fully expand the stent or stent graft within the new tract.

Technical success was defined as adequate flow through the new conduit and into the target outflow vein without extravasation into the surrounding tissue.

Balloon dilatation and stent selection

The starting size of the balloon dilatation depended upon the outflow vein. Usually, the sequential dilatation was initiated with a 4 mm angioplasty balloon (Blue Max, Meditech/Boston Scientific, Watertown, MA) and ended with an 8 mm balloon. In patients where the fistula had

not fully matured, the vein wall was compliant, and the tract remained patent following angioplasty dilatation. However, the thick walls of grafts and mature fistulas were more likely to display elastic recoil, requiring concentric stent placement (Wallstent, 8mm–12mm×40mm–80mm: Natick, MA; Sentinol, 8mm–10mm×40mm–150mm: Meditech/Boston Scientific, Watertown, MA; Protégé Ever-Flex, 10mm×60–80mm: EV3, Minneapolis, MN; Viabahn, 8mm×50mm–100mm: WL Gore & Associates, Flagstaff, AZ, USA; Fluency, 8mm–10mm×40mm–80mm: Bard Peripheral Vascular, Tempe, AZ).

The stents were usually inserted from the antegrade access point B, but could also be placed from the retrograde access point C. Access point A was found to be a poor choice for stent deployment as it did not enable sufficient purchase.

Angioplasty treatment was considered suboptimal if the flow into collateral vessels was greater than that of the primary outflow. The selection of stent length and diameter was determined by the sizes of the hemodialysis access and outflow vein. In general, a stent slightly larger than the angioplasty balloon was used, particularly if the target vein was initially small and future dilatory angioplasties were anticipated to accommodate flow within the fully matured fistula or graft. After the stent was deployed, balloon angioplasty was performed in all cases to expand the stent and further secure its position.

Medications

Heparin was not administered during the course of the procedure. Following the procedure, all patients received 150 mg of clopidogrel orally and were prescribed 75 mg clopidogrel daily for 3 months, if there was no contraindication. The prescription of aspirin varied among the interventionalists: some patients received a single 325 mg bolus, while others were commenced on a concomitant regimen of aspirin 81 mg, to be taken on a daily basis indefinitely. Interventionalists who prescribed a course of post-procedural antibiotics did so for 7 days ciprofloxacin 500 mg once daily or amoxicillin 500 mg twice daily.

Risks and complications

In accordance with the Society of Interventional Radiology (SIR) criteria, major complications are defined as those that required hospitalization, caused permanent adverse sequelae, and death. Minor complications are defined as those that required nominal interventions (7).

The potential risks associated with SNR include extravasation, fragmentation of the target angioplasty balloon, puncture of an adjacent artery, infection, and thrombosis of the access.

Follow-up

Following the procedure, patients returned for consultations at 1 week, 1 month and every 3 months thereafter to determine whether the new outflow tract was functional and patent. Long-term follow-up data was collected in order to evaluate the primary and secondary patencies. Follow-up was obtained during subsequent patient visits, and by means of telephone interviews.

Statistical Analysis

The Society of Interventional Radiology reporting standards for primary patency, primary assisted patency, and secondary patency were utilized. Primary access patency is defined as the time between the SNR procedure and the following repeat intervention. Primary assisted patency is defined as the time between the SNR procedure and any thrombectomy, surgical revision, or access ligation. Primary tract patency is defined as the time between the SNR procedure and any following interventions in the tract, or access ligation. Secondary access patency is defined as the time of patency from the initial intervention until the access was surgically revised or ligated. A Kaplan-Meier analysis was performed to construct a life-table estimate of access patency and tract patency (8).

RESULTS

Outcomes

For the 44 patients, the average distance traversed in the creation of the new tract was 15 mm (range, 1-32mm). During the initial intervention, intra-tract bare metal (19 nitinol, 2 Wallstent) stents were placed in 21 (53%) patients and covered stents in 5 (13%) patients. In the remaining 14 (35%) patients, stents were not used because the subcutaneous distance between the body of the fistula and the outflow vein was 1-2 mm (Tab. II). In patients whose target vein was at a different depth than the access, multiple (average = 3; range, 1–6) needle passes were required before a connection to the vein was established, as the correct needle direction had to be determined in 3 (rather than 2) spatial planes. Some interventionalists, experienced in the use of ultrasound guidance, did not use angiographic triangulation. One patient did not have a single suitable outflow vein, leading the interventionalist to conjoin several small-diameter veins by means of the SNR technique, enable them to heal and dilate over a 2-week period, and then create a tract between this newly-created collateral vessel and the hemodialysis access. (For the purposes of this study, this two-part procedure was considered a single SNR procedure.)

The SNR procedure was unsuccessful in 4 patients.

Three of these patients (with 1 radiocephalic fistula, 1 loop graft, and 1 C-shaped graft) had segments of thrombosis in the outflow target vein that could not be traversed. The fourth patient had a brachiocephalic fistula that the interventionalist attempted to connect to the axillary vein; the tract thrombosed following the initial angioplasty dilatation and subsequent hematoma development caused the procedure to be aborted.

The primary access patency at 3 and 6 months was 25% and 15%, respectively. The primary sharp recanalization tract patency at 3 and 6 months was 69% and 58%, respectively. The secondary patency at 6 and 12 months was 95% and 92%, respectively (Tab. III; Fig. 3). The intervention and thrombectomy rates per access-year were 3.6 and 1.16, respectively. Interventions within the new outflow tract were performed at a rate of 0.94 per access-year.

Follow-Up

All patients underwent fistulography during follow-up, and the average follow-up time was 18.4 months (range, 0.2-48). One patient required a second sharp recanalization procedure after 16 months because of thrombosis of the outflow, which had not been stented during the initial procedure. A covered stent was placed in this access in order to treat angiographically imaged extravasation in the SNR tract. Twenty-one patients required angioplasty treatments of the new outflow tract during subsequent visits; the remaining 19 patients did not require further interventions within the tract. Sixteen patients received 22

TABLE II - RESULTS OF SUCCESSFULLY RECANALIZED HEMODIALYSIS ACCESSES (N=40)*

Connecting Outflow Vein	Axillary = 1 (3) Basilic = 12 (30) Brachial = 14 (35) Cephalic = 9 (23) Median Cubital = 1 (3) Subclavian = 2 (5) Other = 1 (3)
Intra-Tract Stent Placement During Initial Procedure	Angioplasty Only = 14 (35) Wallstent = 2 (5) Bare Nitinol = 19 (48) Covered = 5 (13)
Intra-Tract Interventions During Follow-Up	Angioplasty Only = 47 (in 11 patients) Wallstent = 3 (in 3 patients) Bare Nitinol = 11 (in 9 patients) Covered = 8 (in 8 patients)
Average Ultimate Tract Dilatation Diameter	8 mm (range, 4-10)
Average Tract Length	15 mm (range, 1-32)
Average Follow-up Time	18.4 months (range, 0.2-48)
*Number (percentage).	

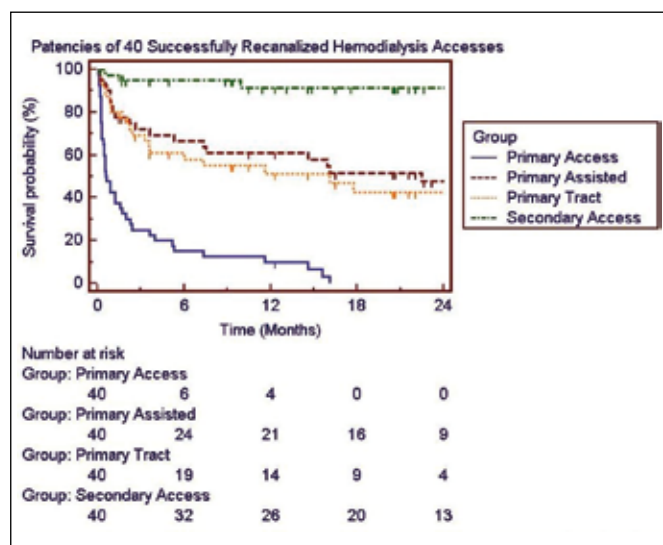


Fig. 3 - Kaplan-Meier curve of tract and access patencies.

TABLE III - PATENCIES OF 40 SUCCESSFULLY RECANALIZED HEMODIALYSIS ACCESSES

Time (Months)	Primary Access	Primary Assisted	Primary Tract	Secondary Access
3	25%	72%	69%	95%
6	15%	66%	58%	95%
12	10%	61%	51%	92%
18	0%	52%	42%	92%
24	0%	47%	42%	92%

additional stents (3 bare steel, 11 bare nitinol, 8 covered) in the new tract in order to maintain suitable patency (Tab. II). Additional procedures included MILLER banding (9) for access flow reduction ($n = 11$), coil embolization or ligation of collateral vessels ($n = 14$), and coil embolization of the distal radial artery (10) to treat digital ischemia in patients with Brescia-Cimino fistulas ($n = 2$).

Four accesses were abandoned during the course of follow-up (2 because of recurrent thrombosis, 1 because of Steal syndrome, and 1 because of extensive stent placement in the mid-fistula that precluded cannulation for hemodialysis). Four patients died during follow-up.

Complications

Minor extravasation occurred in all patients. Thirteen patients experienced mild hematoma formation, which resolved with conservative therapy; 1 patient in whom the SNR tract thrombosed following initial angioplasty experienced hematoma formation, treated with covered stent placement (this was one of the four technical failures).

Aneurysm growth occurred in 2 patients, although this was symptomatic in only one and treated with a covered stent. An intra-tract stent fractured in one patient, although the resultant thrombosis was successfully treated and a covered stent placed to maintain patency. Stent migration occurred in one patient, and the stent was secured via angioplasty with no adverse sequelae. No major complications occurred during follow-up.

DISCUSSION

The venous outflow section of a hemodialysis access is the region most prone to stenosis and thrombosis (11, 12). In many cases, chronic rethrombosis of an access is directly related to a tortuous outflow or an occluded primary outflow channel (1, 13). In the setting of a high flow arteriovenous access, in particular the radiocephalic (Brescia-Cimino) fistula, normal variations in venous anatomy may act as relative occlusions. Hemodialysis patients are also at risk of peripheral and central venous stenoses as a result of long-term indwelling venous catheters (14). While angioplasty (3) and various stent types (15-17) have been useful in maintaining outflow patency, a torturous outflow can be difficult to remedy. However, the venous system contains significant pathway redundancy, and this characteristic can be exploited to link suboptimal outflow routes to patent adjacent veins to achieve straight-line flow.

Besides new access creation, surgical treatments consist of access flow rerouting by connecting a bypass graft to a more suitable outflow vein. There are few publications reporting the outcomes of such "jump grafts" (1, 18-21). Barone et al. (21) has reported a series of 14 thrombosed loop grafts that were salvaged with a 5 cm bypass graft, achieving a secondary patency of 64% at 24 months. A subsequent publication by the same authors (20) used 6-8 cm bypass grafts to attain 3-month and 6-month primary patencies of 82% and 56%, respectively, in a cohort of 32 grafts.

Connecting vascular structures by advancing small-gauge needles to open a pathway and then using angioplasty dilatation and stent placement to preserve the tract is a well-reported endovascular technique (22-32). Goo et al. successfully recanalized 31 of 33 occluded central veins in 33 hemodialysis patients, with an average occlusion length of 17.3 mm and secondary patency of 56% at 12 months (27). Farrell et al recommended insertion of the recanalization needle in a cephalad rather than caudal direction because of the higher venous pressure above the occlusion (25). Gupta et al (29) and Murphy et al (22) used traditional guidewire techniques to determine the correct direction of needle puncture, along with a contrast-filled occlusion balloon that acted as a target for the needle. Although ultrasound guidance obviates the need for triangulation, using a balloon as a target is useful in outflow

veins that are small in caliber or difficult to reach because of the distance or angle.

Consistent with observations by Barone et al. (20), we have found the most suitable connecting vein to be the basilic vein, as the cephalic, brachial, and median cubital veins tend to have smaller diameters (33). However, the endovascular sharp needle technique is not limited by the diameter of the connecting vein, as small veins can be converted into suitable outflow vessels by means of angioplasty dilatation (34). By contrast, the connecting vein of a bypass graft must have a sufficiently large diameter in order for the surgeon to successfully construct the anastomosis.

The sharp needle technique is limited by the distance between the AV access and the targeted juxtaposed vein. When the subcutaneous distance between the access and the target vein was 1-2 mm, a durable tract could be established without the need for stent placement. Greater distances generally required placement of a stent in order to maintain tract patency. Although the sharp recanalization procedure is particularly difficult when the subcutaneous depth of the connecting vein is different from that of the access, snares and ultrasonography can be used to align the two vessels (35).

The lack of major complications suggests that experienced interventionalists can safely perform this procedure. Our low primary patencies must be considered in the context of the patient pool (all patients presented chronically occluded accesses) and the need for multiple re-interventions to maintain access patency (36).

With a 91% rate of technical success and only one patient requiring a second recanalization procedure, our study suggests that this technique is effective to treat chro-

nically occluded outflow in hemodialysis accesses. This study reveals the feasibility and safety of sharp needle recanalization, and the 24-month secondary patency of 92% attests to the durability of this treatment.

Although the retrospective nature of this study precludes the delineation of precise patient selection criteria, it may be the best option for patients with failing accesses and suboptimal vasculature. Such patients are poor candidates for secondary fistulas and may progress better if the lifetime of their current access is extended instead. However, this must be balanced against the risk of extensive stent placement precluding the insertion of hemodialysis needles.

ACKNOWLEDGEMENTS

Artwork for Figures 1 and 2 was prepared by Carl Boisson (*goldenchylde@gmail.com*). Michael Alesi, RT, and James Smith, RT, provided expert technical advice in order to make these procedures possible and successful.

Conflict of interest: We have had no involvement that might raise the question of bias in the work reported or in the conclusions, implications, or opinions stated.

Address for correspondence:
Gregg A. Miller, MD
American Access Care of Brooklyn
577 Prospect Ave,
Brooklyn, NY 11215
vascular1@att.net

REFERENCES

1. Palder SB, Kirkman RL, Whittemore AD, Hakim RM, Lazarus JM, Tilney NL. Vascular access for hemodialysis. Patency rates and results of revision. *Ann Surg.* 1985; 202: 235-9.
2. Kanterman RY, Vesely TM. Graft-to-vein fistulas associated with polytetrafluoroethylene dialysis grafts: diagnosis and clinical significance. *J Vasc Interv Radiol.* 1995; 6: 267-71.
3. Marston WA, Criado E, Jaques PF, Mauro MA, Burnham SJ, Keagy BA. Prospective randomized comparison of surgical versus endovascular management of thrombosed dialysis access grafts. *J Vasc Surg.* 1997; 26: 373-80; discussion 80-1.
4. Criado E, Marston WA, Jaques PF, Mauro MA, Keagy BA. Proximal venous outflow obstruction in patients with upper extremity arteriovenous dialysis access. *Ann Vasc Surg.* 1994; 8: 530-5.
5. Oakes DD, Sherck JP, Cobb LF. Surgical salvage of failed radiocephalic arteriovenous fistulae: techniques and results in 29 patients. *Kidney Int.* 1998; 53: 480-7.
6. Declaration of Helsinki. Ethical principles for medical research involving human subjects. *J Indian Med Assoc.* 2009; 107: 403-5.
7. Aruny JE LC, Cardella JF, Cole PE, Davis A, Grooz AT, et al. Quality improvement guidelines for percutaneous management of the thrombosed or dysfunctional dialysis access. *J Vasc Interv Radiol.* 2003; 14: S247-53.
8. Gray RJ, Sacks D, Martin LG, Trerotola SO. Reporting standards for percutaneous interventions in dialysis access. *J Vasc Interv Radiol.* 2003; 14: S433-42.
9. Miller GA, Goel N, Friedman A, Khariton A, Jotwani MC, Savransky Y, et al. The MILLER banding procedure is an effective method for treating dialysis-associated steal syndrome. *Kidney Int.* 2010; 77: 359-66.

10. Miller GA, Khariton K, Kardos SV, Koh E, Goel N, Khariton A. Flow interruption of the distal radial artery: treatment for finger ischemia in a matured radiocephalic AVF. *J Vasc Access*. 2008; 9: 58-63.
11. Maya ID, Oser R, Saddekni S, Barker J, Allon M. Vascular access stenosis: comparison of arteriovenous grafts and fistulas. *Am J Kidney Dis*. 2004; 44: 859-65.
12. Maya ID, Smith T, Young CJ, Allon M. Is surgical salvage of arteriovenous grafts feasible after unsuccessful percutaneous mechanical thrombectomy? *Semin Dial*. 2008; 21: 174-7.
13. Mickley V. Stenosis and thrombosis in haemodialysis fistulae and grafts: the surgeon's point of view. *Nephrol Dial Transplant*. 2004; 19: 309-11.
14. MacRae JM, Ahmed A, Johnson N, Levin A, Kiaii M. Central vein stenosis: a common problem in patients on hemodialysis. *ASAIO J*. 2005; 51: 77-81.
15. Naoum JJ, Irwin C, Hunter GC. The use of covered nitinol stents to salvage dialysis grafts after multiple failures. *Vasc Endovascular Surg*. 2006; 40: 275-9.
16. Turmel-Rodrigues L, Pengloan J, Baudin S, Testou D, Abaza M, Dahdah G, et al. Treatment of stenosis and thrombosis in haemodialysis fistulas and grafts by interventional radiology. *Nephrol Dial Transplant*. 2000; 15: 2029-36.
17. Haage P, Vorwerk D, Piroth W, Schuermann K, Guenther RW. Treatment of hemodialysis-related central venous stenosis or occlusion: results of primary Wallstent placement and follow-up in 50 patients. *Radiology*. 1999; 212: 175-80.
18. Schulak JA, Lukens ML, Mayes JT. Salvage of thrombosed forearm polytetrafluoroethylene vascular access grafts by reversal of flow direction and venous bypass grafting. *Am J Surg*. 1991; 161: 485-7.
19. Suliman A, Greenberg JJ, Angle N. Surgical bypass of symptomatic central venous obstruction for arteriovenous fistula salvage in hemodialysis patients. *Ann Vasc Surg*. 2008; 22: 203-9.
20. Barone GW, Hudec WA, Webb JW. Antecubital Jump Revisions for Salvaging Hemodialysis Grafts. *Vasc Surg*. 2000; 34: 11-5.
21. Barone GW, Hudec WA. Primary antecubital jump bypass grafts for hemoaccess. *J Am Coll Surg*. 1998; 187: 106-7.
22. Murphy TP, Webb MS. Percutaneous venous bypass for refractory dialysis-related subclavian vein occlusion. *J Vasc Interv Radiol*. 1998; 9: 935-9.
23. Honnef D, Wingen M, Gunther RW, Haage P. Sharp central venous recanalization by means of a TIPS needle. *Cardiovasc Intervent Radiol*. 2005; 28: 673-6.
24. Athreya S, Scott P, Annamalai G, Edwards R, Moss J, Robertson I. Sharp recanalization of central venous occlusions: a useful technique for haemodialysis line insertion. *Br J Radiol*. 2009; 82: 105-8.
25. Farrell T, Lang EV, Barnhart W. Sharp recanalization of central venous occlusions. *J Vasc Interv Radiol*. 1999; 10: 149-54.
26. Lang EV, Farrell T, Vrachliotis TG, Brophy DP. Sharp Recanalization for Chronic Central Venous Occlusions. *Tech Vasc Interv Radiol*. 2000; 3: 21-8.
27. Goo DE, Kim YJ, Choi DL, Park SI, Yang SB, Moon C, et al. Use of a rosch-uchida needle for recanalization of refractory dialysis-related central vein occlusion. *AJR Am J Roentgenol*. 194: 1352-6.
28. Ferral H, Bjarnason H, Wholey M, Lopera J, Maynar M, Castaneda-Zuniga WR. Recanalization of occluded veins to provide access for central catheter placement. *J Vasc Interv Radiol*. 1996; 7: 681-5.
29. Gupta H, Murphy TP, Soares GM. Use of a puncture needle for recanalization of an occluded right subclavian vein. *Cardiovasc Intervent Radiol*. 1998; 21: 508-11.
30. Kuo MD, Son DH, Miller FJ. Salvage of a failing dialysis graft by percutaneous creation of a jump bypass graft. *J Vasc Interv Radiol*. 2007; 18: 1054-8.
31. Chen MC, Liang HL, Wu DK, Weng MJ, Liu GC, Pan HB, et al. Percutaneous vein graft reanastomosis with use of a covered stent to salvage a thrombosed hemodialysis graft. *J Vasc Interv Radiol*. 2005; 16: 1385-9.
32. Anil G, Taneja M. Revascularization of an occluded brachiocephalic vein using Outback-LTD re-entry catheter. *J Vasc Surg*. Published online 7/6/2010.
33. Shima H, Ohno K, Shimizu T, Michi K, Egawa K, Takiguchi R. Anatomical study of the valves of the superficial veins of the forearm. *J Craniomaxillofac Surg*. 1992; 20: 305-9.
34. Miller GA, Goel N, Khariton A, Friedman A, Savransky Y, Trusov I, et al. Aggressive approach to salvage non-maturing arteriovenous fistulae: a retrospective study with follow-up. *J Vasc Access*. 2009; 10: 183-91.
35. Heller SLaTWC. Percutaneous creation of a venous anastomosis in a native hemodialysis fistula. *J Vasc Interv Radiol*. 2009; 20: 1371-5.
36. Mickley V GJ, Rilinger N, Storck M, Abendroth D. Stenting of central venous stenoses in hemodialysis patients: long-term results. *Kidney Int*. 1997; 51: 277-80.